

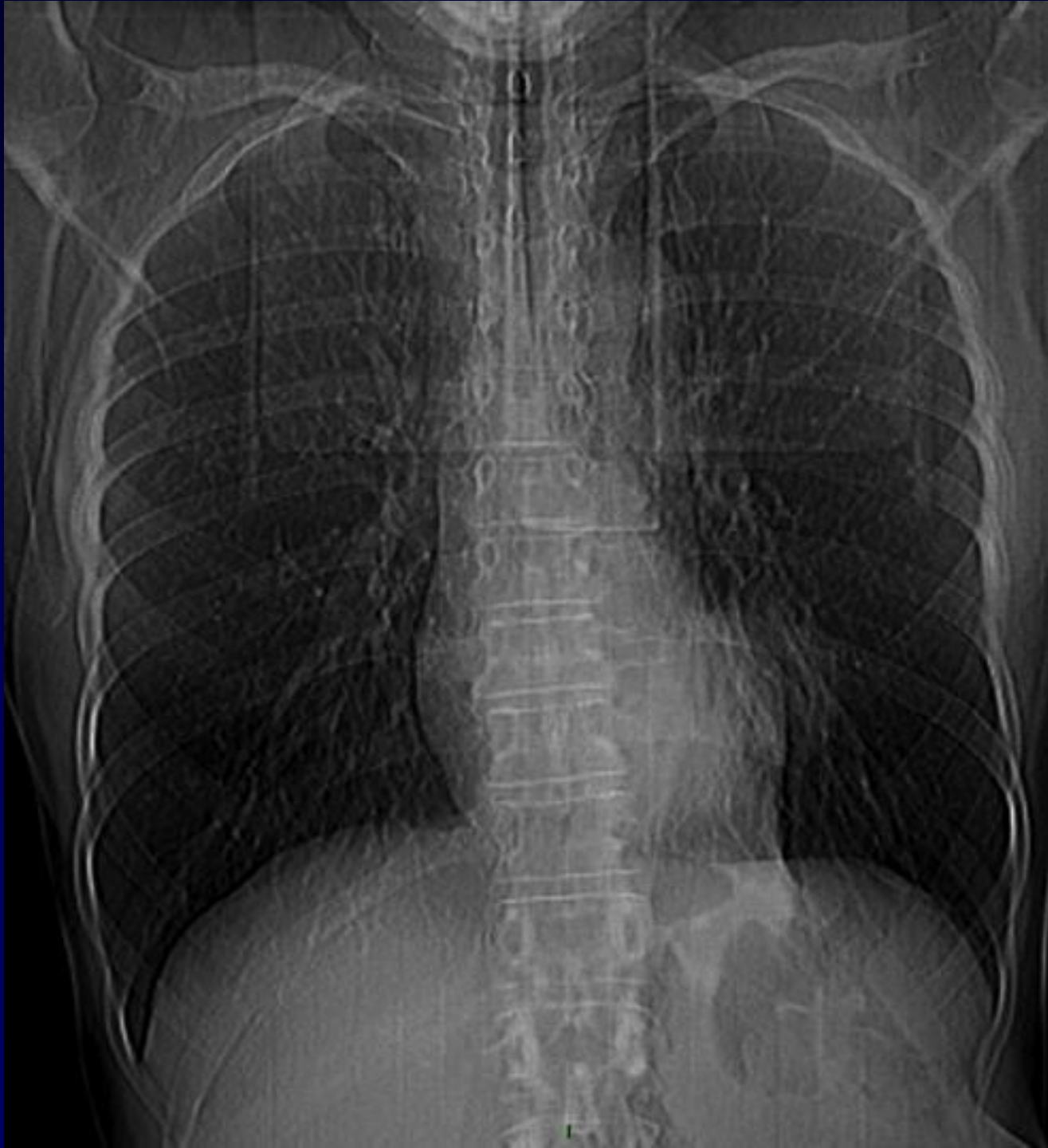
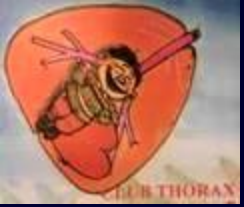
A Khalil

MF Carette

Femme de 56 ans

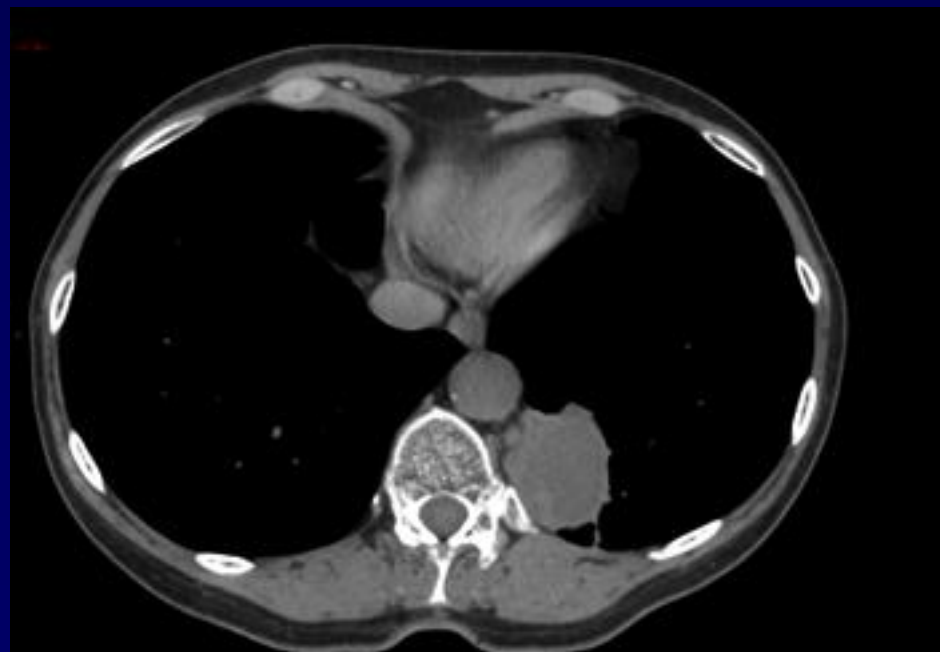
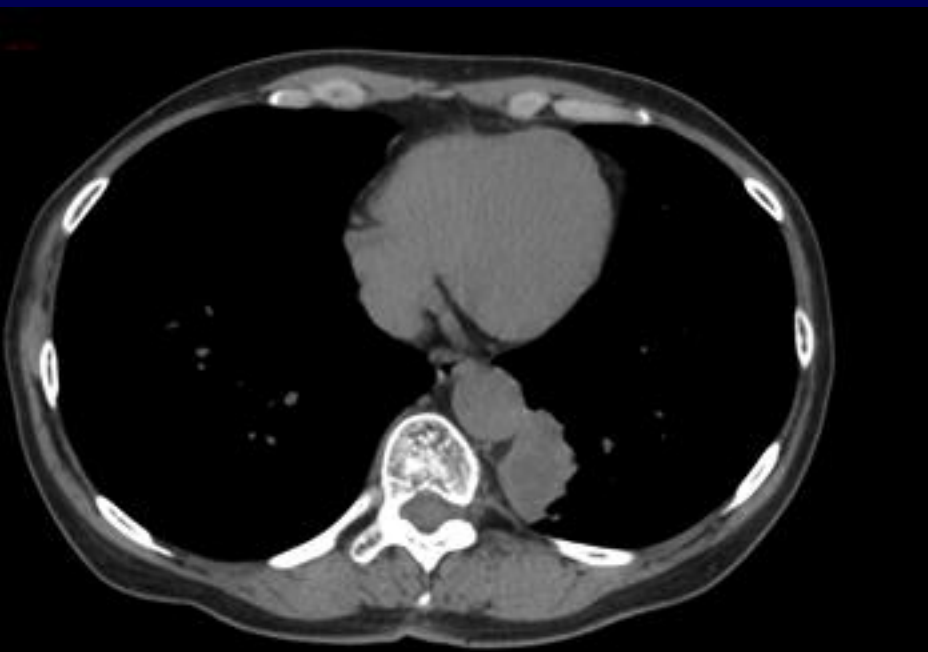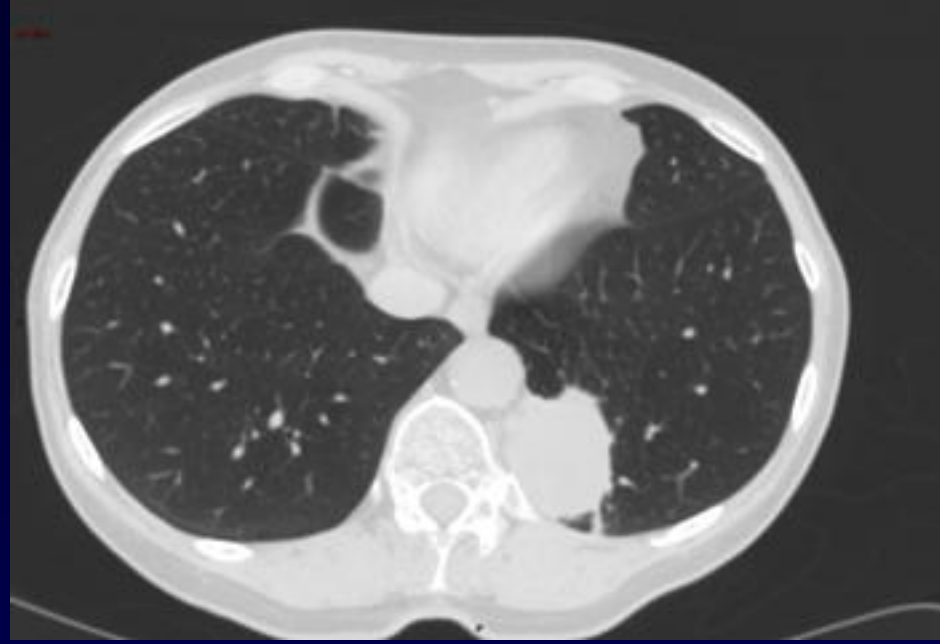
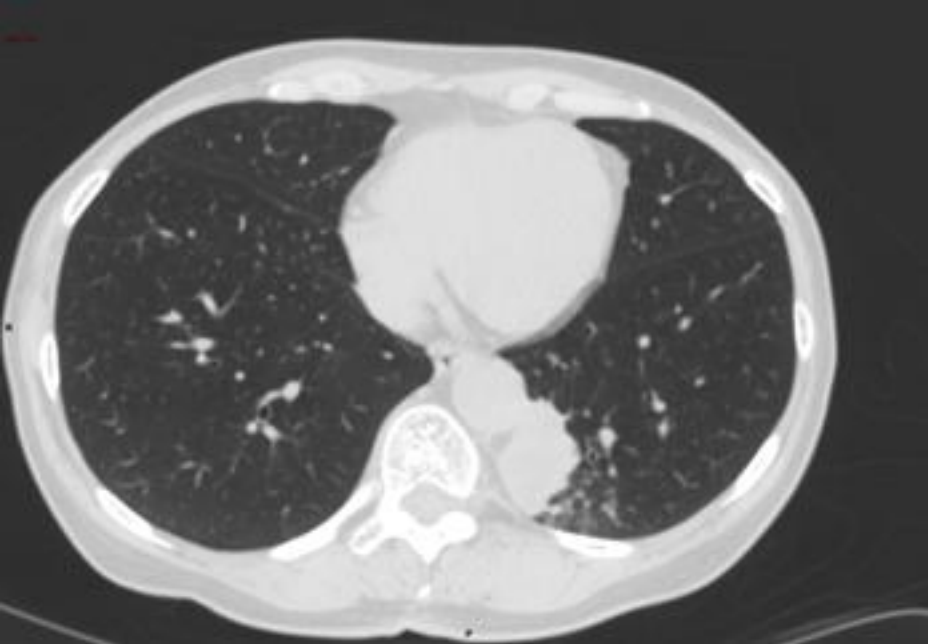
Consulte pour une toux

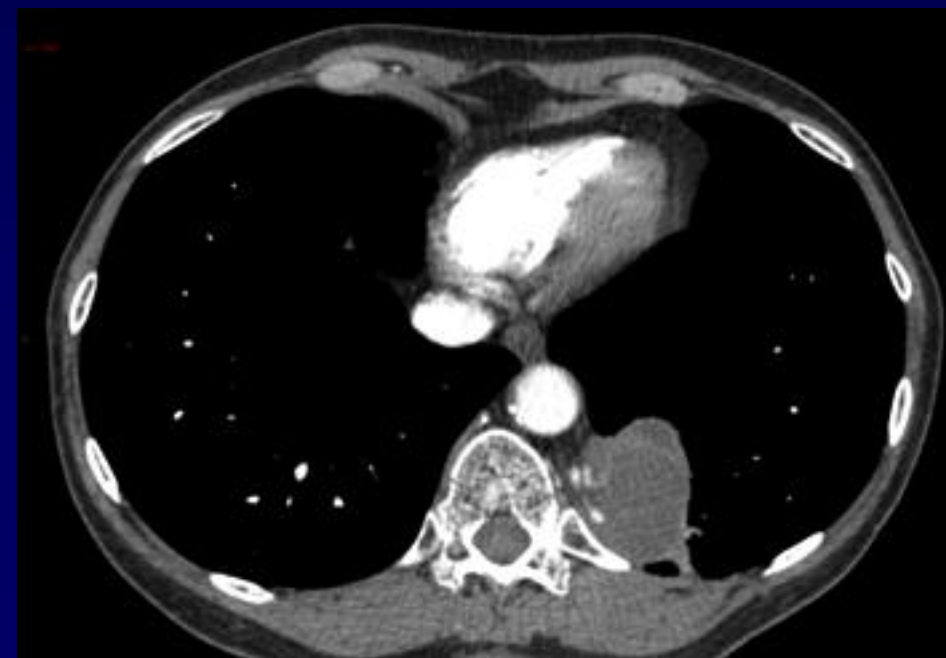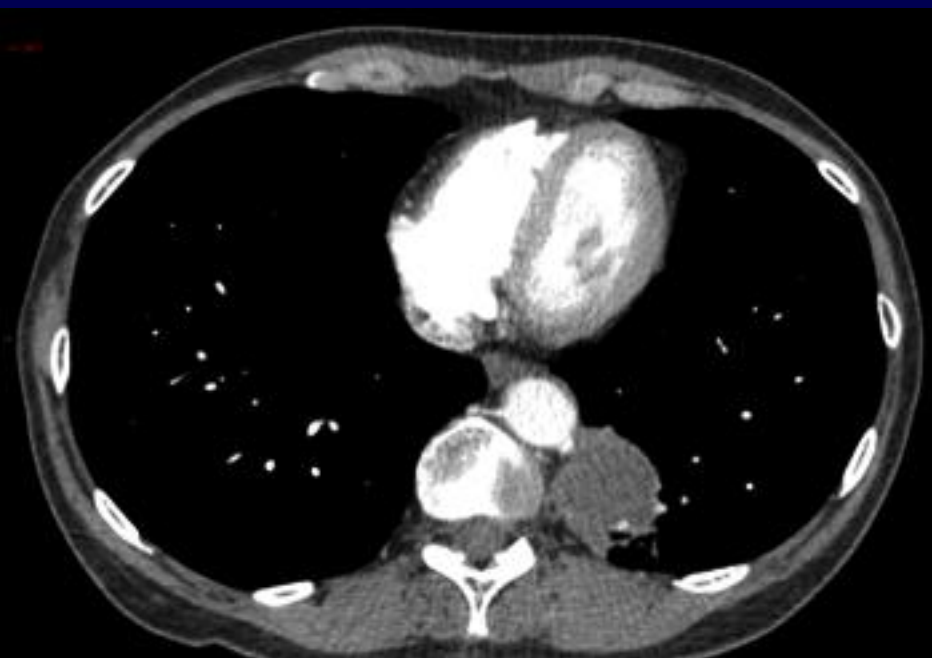
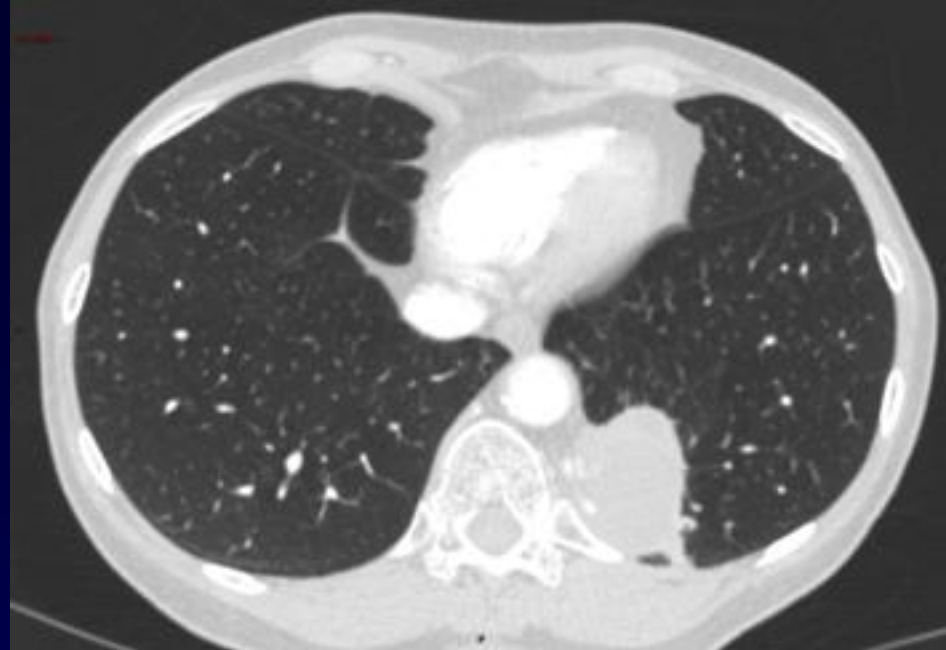
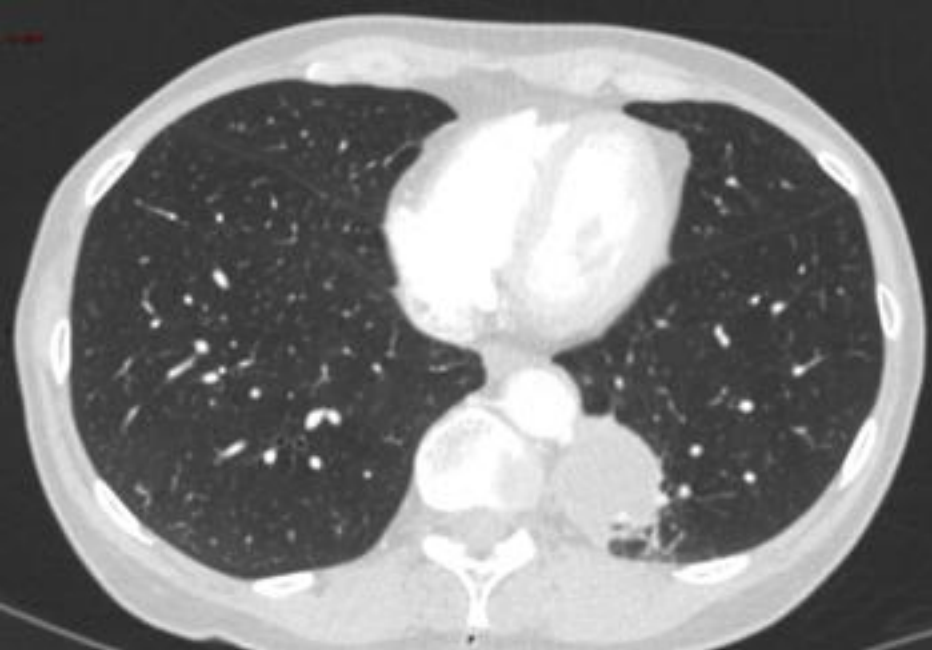
Une radiographie thoracique est pratiquée

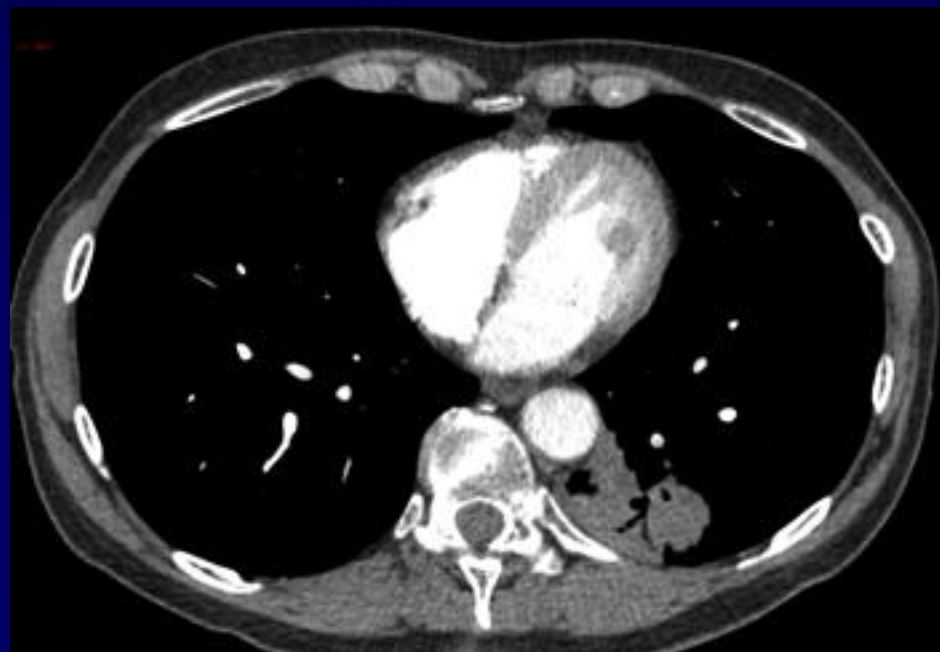
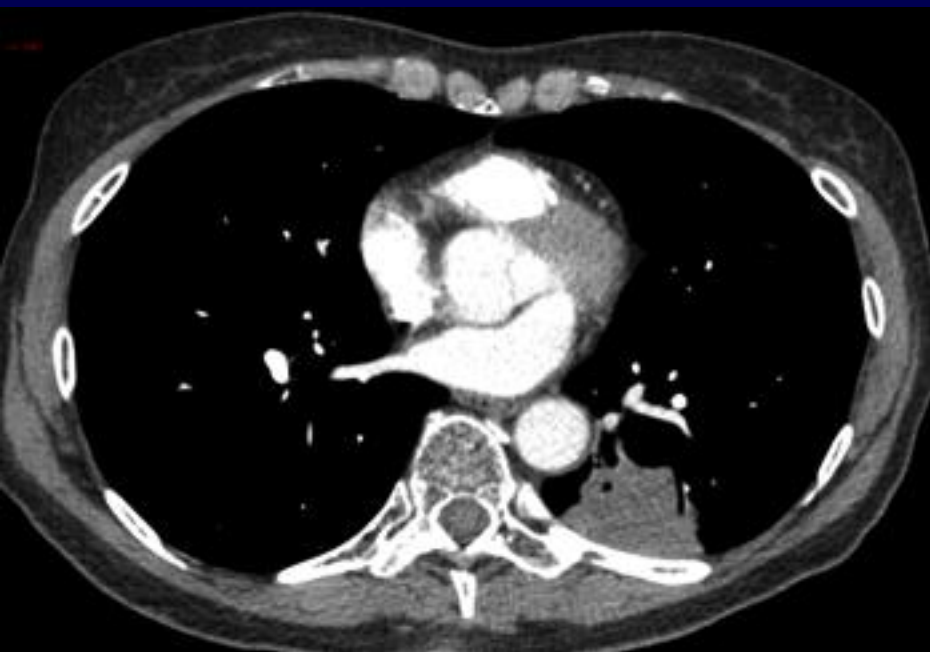
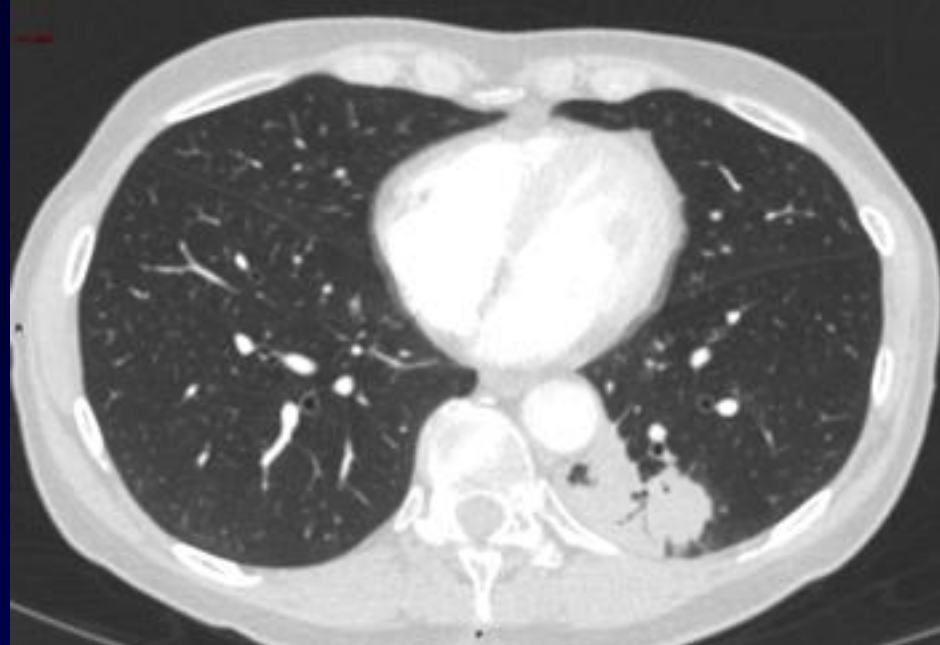
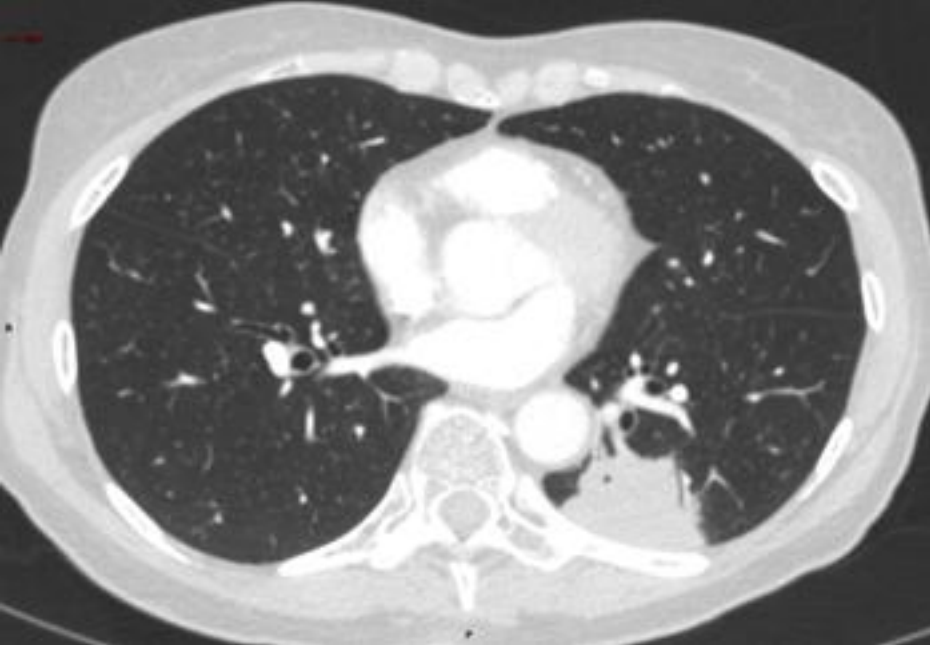
Un examen TDM est demandé  
pour complément d'exploration

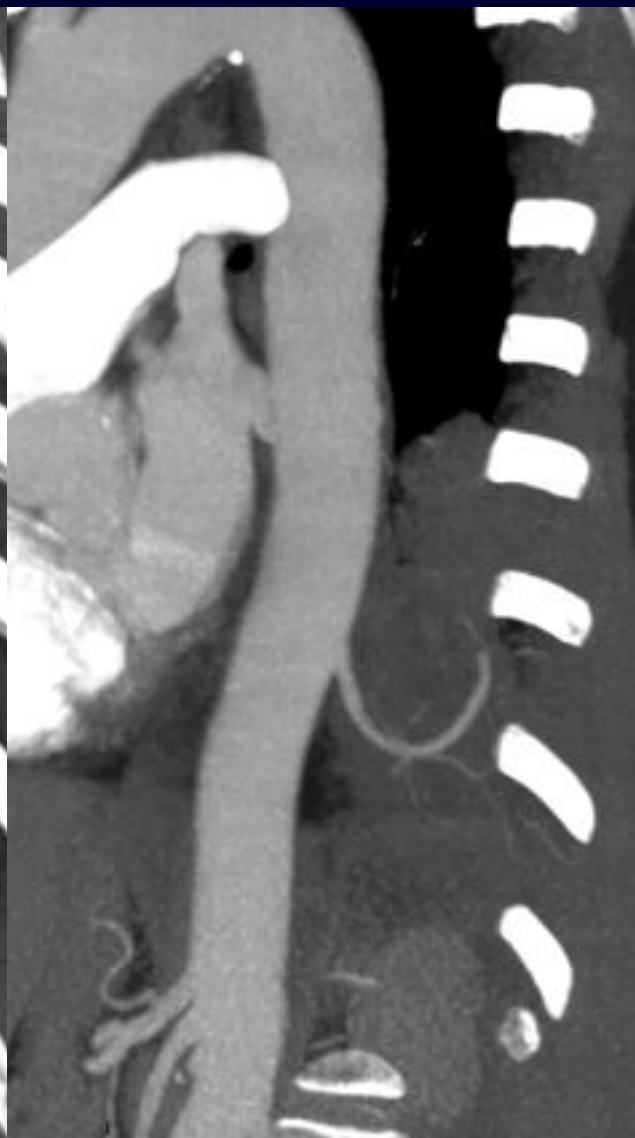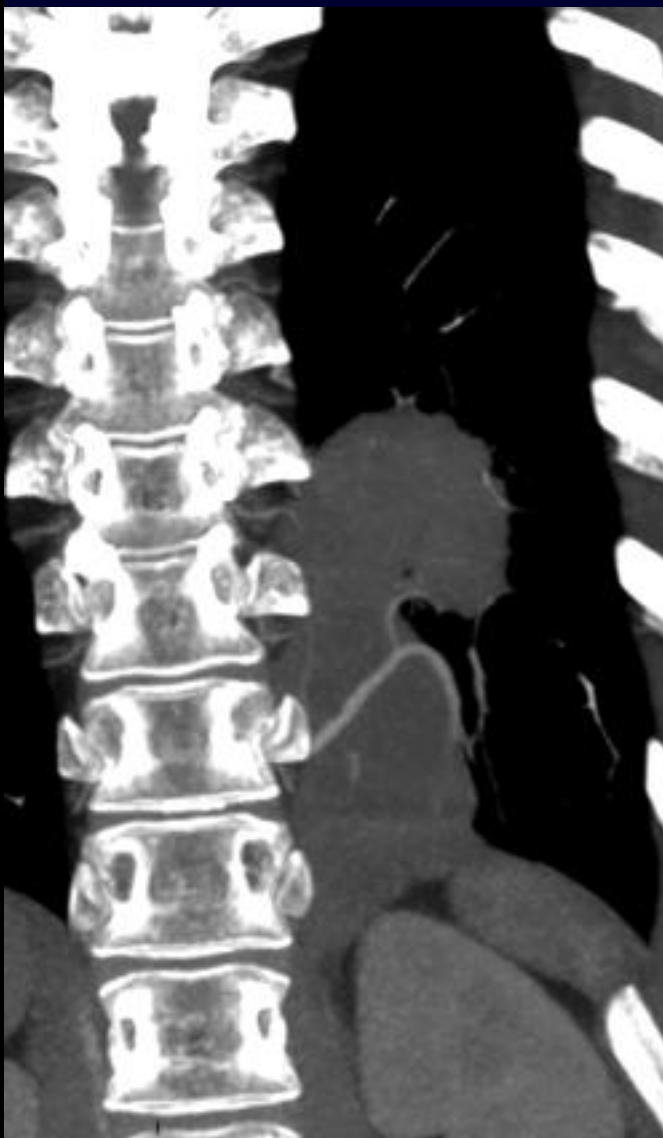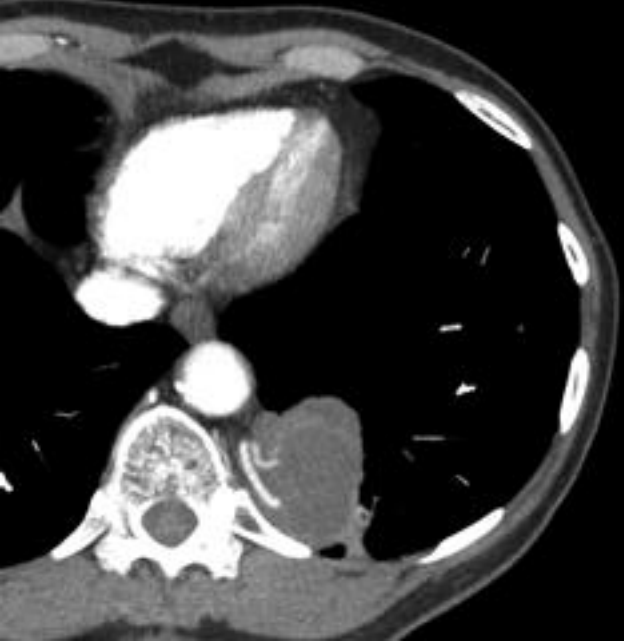
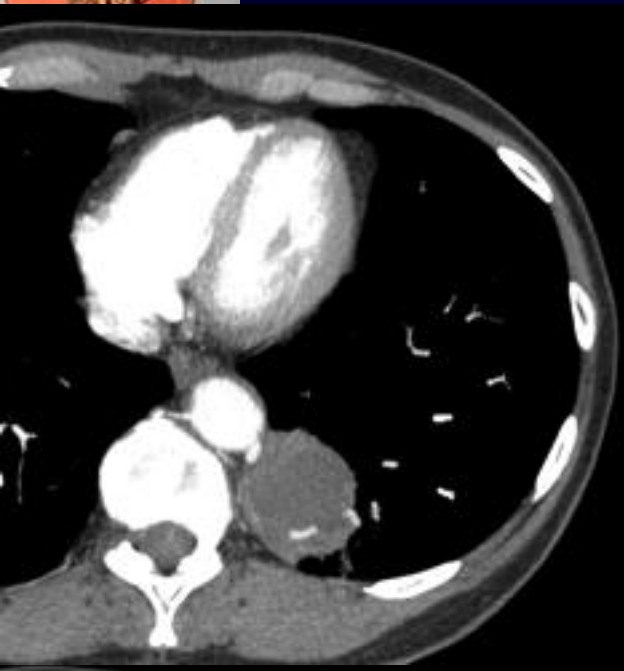




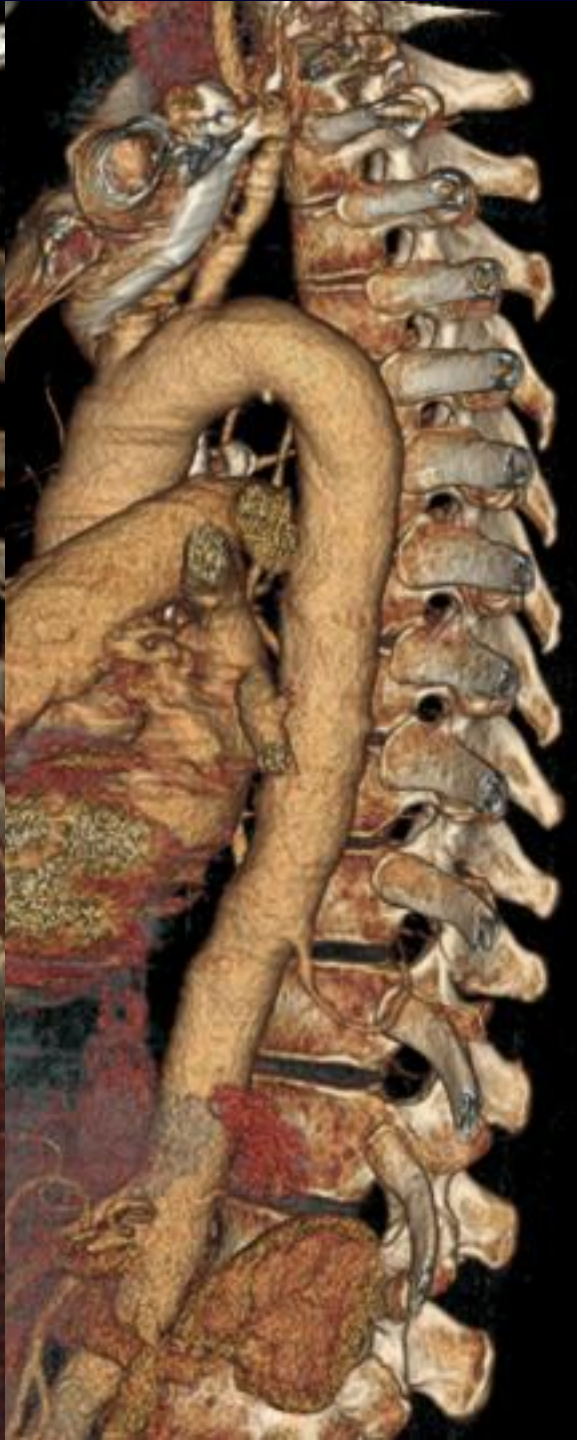
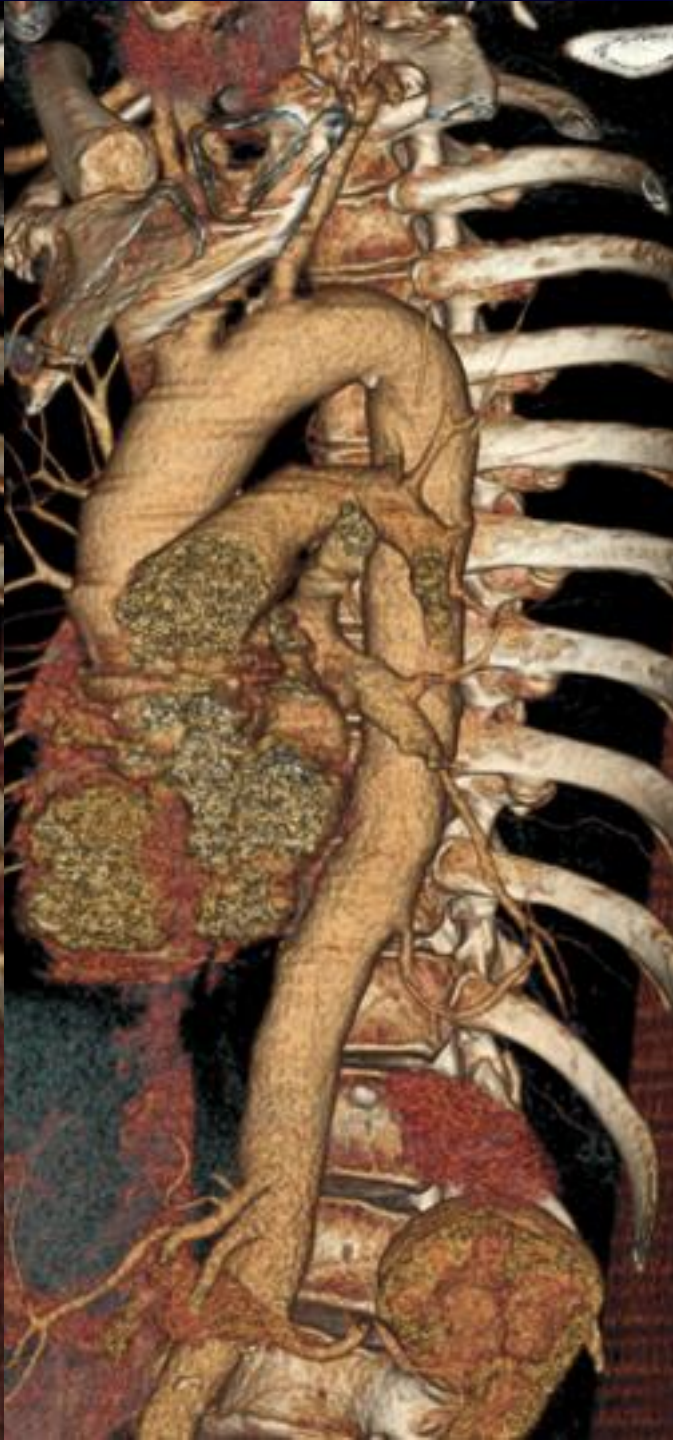
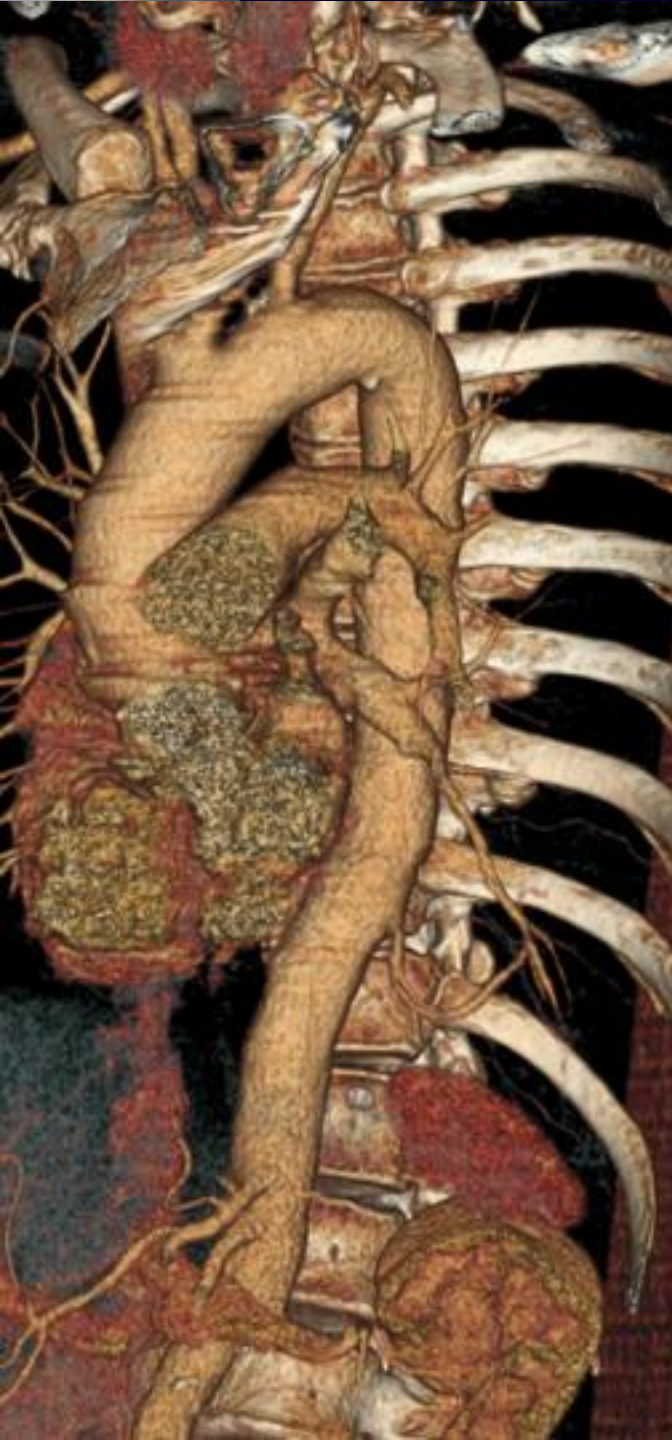

Diagnostic ?







## Diagnostic

Séquestration broncho-pulmonaire  
avec foyer de surinfection pulmonaire